

Patient Name: John Doe	Requesting Physician: David A. Smith, M.D.	Collected: 03/13/2009
Sex: Male	Client/Group Facility: Urology Associates, PA	Received: 03/20/2009
Date of Birth (Age): 10/10/1958 (50 years)	Additional Recipient: Mark Howard, M.D.	Reported: 03/23/2009
SSN: 212-22-2234	Submitting Pathologist: Tim Jackson, M.D.	Case #: S09-123445
Patient ID: 23445921	Specimen ID: 232323233	Req #:

Prostate Biopsy

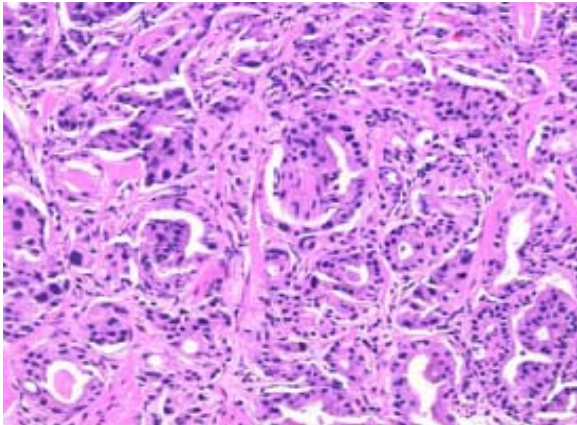
CLINICAL HISTORY

Prostate induration with associated elevated PSA 8.9 ng/mL.

CASE SUMMARY

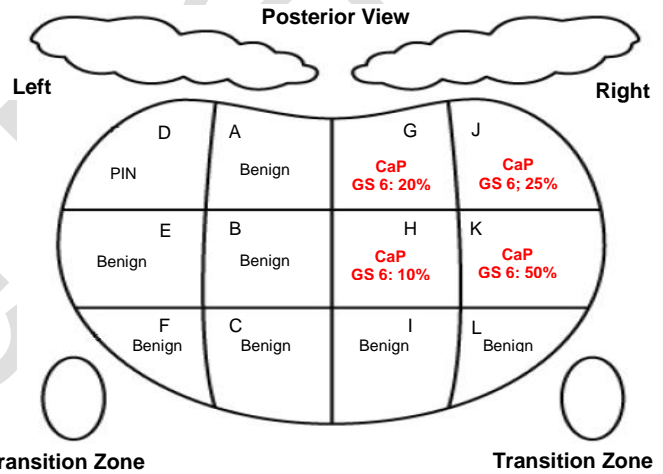
Adenocarcinoma of the prostate, Gleason Score 6(3+3), involving four cores (50%, 25%, 20%, 10%).

PHOTOMICROGRAPH



Adenocarcinoma, Gleason 6(3+3)

DIAGNOSTIC MAP



CaP: Cancer **PIN:** Prostatic Intraepithelial Neoplasia
Atyp: Atypical

FINAL DIAGNOSIS

SPECIMEN (CORE BIOPSY)

- A) Left Base, Biopsy: Benign prostate
- B) Left Mid, Biopsy: Benign prostate
- C) Left Apex, Biopsy: Benign prostate
- D) Left Lateral Base, Biopsy: Prostatic intraepithelial neoplasia (PIN; high grade)
- E) Left Lateral Mid, Biopsy: Benign prostate
- F) Left Lateral Apex, Biopsy: Benign prostate
- G) Right Base, Biopsy: **Adenocarcinoma, Gleason Score 6(3+3), involving 20% of the total biopsy length**
- H) Right Mid, Biopsy: **Adenocarcinoma, Gleason Score 6(3+3), involving 10% of the total biopsy length**
- I) Right Apex, Biopsy: Benign prostate
- J) Right Lateral Base, Biopsy: **Adenocarcinoma, Gleason Score 6(3+3), involving 25% of the total biopsy length**
- K) Right Lateral Mid, Biopsy: **Adenocarcinoma, Gleason Score 6(3+3), involving 50% of the total biopsy length**
- L) Right Lateral Apex, Biopsy: Benign prostate

Patient Name: John Doe	Requesting Physician: David A. Smith, M.D.	Collected: 03/13/2009
Sex: Male	Client/Group Facility: Urology Associates, PA	Received: 03/20/2009
Date of Birth (Age): 10/10/1958 (50 years)	Additional Recipient: Mark Howard, M.D.	Reported: 03/23/2009
SSN: 212-22-2234	Submitting Pathologist: Tim Jackson, M.D.	Case #: S09-123445
Patient ID: 23445921	Specimen ID: 232323233	Req #:

Prostate Biopsy

SOURCE

- A) Prostate, Left Base
- B) Prostate, Left Mid
- C) Prostate, Left Apex
- D) Prostate, Left Lateral Base
- E) Prostate, Left Lateral Mid
- F) Prostate, Left Lateral Apex
- G) Prostate, Right Base
- H) Prostate, Right Mid
- I) Prostate, Right Apex
- J) Prostate, Right Lateral Base
- K) Prostate, Right Lateral Mid
- L) Prostate, Right Lateral Apex

GROSS DESCRIPTION

- A) Tan-white soft tissue received in formalin measuring 1.0 cm: 1 piece(s) submitted in 1 cassette(s).
- B) Tan-white soft tissue received in formalin measuring 0.9 cm: 1 piece(s) submitted in 1 cassette(s).
- C) Tan-white soft tissue received in formalin measuring 0.2 cm: 1 piece(s) submitted in 1 cassette(s).
- D) Tan-white soft tissue received in formalin measuring 1.2 cm: 1 piece(s) submitted in 1 cassette(s).
- E) Tan-white soft tissue received in formalin measuring 1.0 cm: 1 piece(s) submitted in 1 cassette(s).
- F) Tan-white soft tissue received in formalin measuring 0.4 cm: 1 piece(s) submitted in 1 cassette(s).
- G) Tan-white soft tissue received in formalin measuring 1.3 cm: 1 piece(s) submitted in 1 cassette(s).
- H) Tan-white soft tissue received in formalin measuring 1.7 cm: 1 piece(s) submitted in 1 cassette(s).
- I) Tan-white soft tissue received in formalin measuring 1.4 cm: 1 piece(s) submitted in 1 cassette(s).
- J) Tan-white soft tissue received in formalin measuring 0.9 cm: 1 piece(s) submitted in 1 cassette(s).
- K) Tan-white soft tissue received in formalin measuring 1.0 cm: 1 piece(s) submitted in 1 cassette(s).
- L) Tan-white soft tissue received in formalin measuring 1.0 cm: 1 piece(s) submitted in 1 cassette(s).

COMMENTS

Immunohistochemical stains (HMWK, P504S and p63) on (G, H, J and K) support the diagnosis.

Patient Name: John Doe	Requesting Physician: David A. Smith, M.D.	Collected: 03/13/2009
Sex: Male	Client/Group Facility: Urology Associates, PA	Received: 03/20/2009
Date of Birth (Age): 10/10/1958 (50 years)	Additional Recipient: Mark Howard, M.D.	Reported: 03/23/2009
SSN: 212-22-2234	Submitting Pathologist: Tim Jackson, M.D.	Case #: S09-123445
Patient ID: 23445921	Specimen ID: 232323233	Req #:

Prostate Biopsy

If you have any questions on this report please do not hesitate to contact the BioVantra client support center at (866) 627-8221.

Peter A. Tsivis, M.D.

Pathologist Electronic Signature

03/23/2009

Date

Photomicrograph and diagnostic map are symbolic representations of the key findings of the pathology report. The photomicrograph and diagnostic map are not intended to replace a complete review and reading of the final diagnostic report provided.