

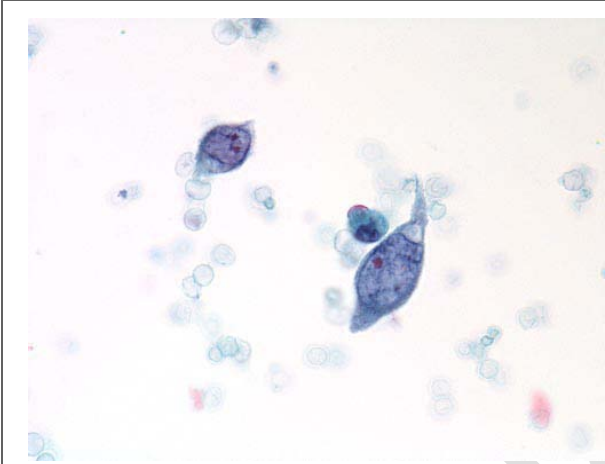
<b>Patient Name:</b> John Doe	<b>Requesting Physician:</b> David A. Smith, M.D.	<b>Collected:</b> 03/13/2009
<b>Sex:</b> Male	<b>Client/Group Facility:</b> Urology Associates, PA	<b>Received:</b> 03/20/2009
<b>Date of Birth (Age):</b> 10/10/1958 (50 years)	<b>Additional Recipient:</b> Mark Howard, M.D.	<b>Reported:</b> 03/23/2009
<b>SSN:</b> 212-22-2234	<b>Submitting Pathologist:</b> Tim Jackson, M.D.	<b>Case #:</b> C09-123445
<b>Patient ID:</b> 23445921	<b>Specimen ID:</b> 232323233	<b>Req #:</b>

## Cytology

### CLINICAL HISTORY

History of bladder cancer. Completed BCG 02/01/2009.

### PHOTOMICROGRAPH



**Tumor cells present.**

### DIAGNOSIS

Urine, Voided-Cytology Liquid Based: **Tumor cells present.**

### SOURCE

Urine, Voided-Cytology Liquid Based

### GROSS DESCRIPTION

Specimen received in PreservCyt solution.  
Volume: 60 cc  
Clarity: Clear  
Color: Yellow  
Specimen was prepared using the Cytyc ThinPrep System.

### COMMENTS

An aliquot of the sample was submitted for UroVysion™ testing. A separate report will follow.

<b>Patient Name:</b> John Doe	<b>Requesting Physician:</b> David A. Smith, M.D.	<b>Collected:</b> 03/13/2009
<b>Sex:</b> Male	<b>Client/Group Facility:</b> Urology Associates, PA	<b>Received:</b> 03/20/2009
<b>Date of Birth (Age):</b> 10/10/1958 (50 years)	<b>Additional Recipient:</b> Mark Howard, M.D.	<b>Reported:</b> 03/23/2009
<b>SSN:</b> 212-22-2234	<b>Submitting Pathologist:</b> Tim Jackson, M.D.	<b>Case #:</b> C09-123445
<b>Patient ID:</b> 23445921	<b>Specimen ID:</b> 232323233	<b>Req #:</b>

## Cytology

If you have any questions on this report please do not hesitate to contact the BioVantra client support center at (866) 627-8221.

**Peter A. Tsvivis, M.D.**

*Pathologist Electronic Signature*

**03/23/2009**

*Date*

Photomicrograph is a symbolic representation of the key findings of the cytology report. The photomicrograph is not intended to replace a complete review and reading of the final diagnostic report provided.