

Patient Name: John Doe	Requesting Physician: David A. Smith, M.D.	Collected: 03/13/2009
Sex: Male	Client/Group Facility: Urology Associates, PA	Received: 03/20/2009
Date of Birth (Age): 10/10/1958 (50 years)	Additional Recipient: Mark Howard, M.D.	Reported: 03/23/2009
SSN: 212-22-2234	Submitting Pathologist: Tim Jackson, M.D.	Case #: S09-123445
Patient ID: 23445921	Specimen ID: 232323233	Req #:

Bladder / Urothelial Biopsy

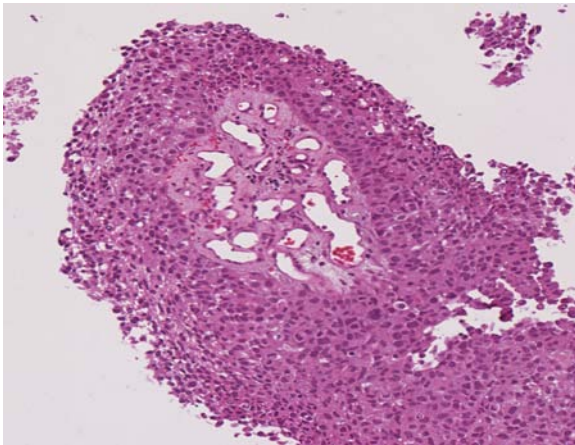
CLINICAL HISTORY

Gross hematuria.

CASE SUMMARY

Transitional cell carcinoma of the urinary bladder, Grade III/III (WHO). Noninvasive; muscle wall identified (Ta).

PHOTOMICROGRAPH



Transitional cell carcinoma of the urinary bladder. Grade III/III (WHO). Noninvasive; muscle wall identified (Ta).

FINAL DIAGNOSIS

SPECIMEN (Biopsy)

- A) Dome, Biopsy: Benign urothelium and submucosa.
- B) Posterior Wall, Biopsy: Benign urothelium and submucosa.
- C) Right Wall, Biopsy: Benign urothelium and submucosa.
- D) Left Wall, Biopsy: Transitional cell carcinoma of the urinary bladder. Grade III/III (WHO). Noninvasive; muscle wall identified (Ta).
- E) Anterior Wall, Biopsy: Benign urothelium and submucosa.
- F) Trigone, Biopsy: Cystitis cystic.
- G) Prostatic Urethra, Biopsy: Benign prostatic urethra.

SOURCE

- A) Bladder, Dome
- B) Bladder, Posterior Wall
- C) Bladder, Right Wall
- D) Bladder, Left Wall
- E) Bladder, Anterior Wall

Patient Name: John Doe	Requesting Physician: David A. Smith, M.D.	Collected: 03/13/2009
Sex: Male	Client/Group Facility: Urology Associates, PA	Received: 03/20/2009
Date of Birth (Age): 10/10/1958 (50 years)	Additional Recipient: Mark Howard, M.D.	Reported: 03/23/2009
SSN: 212-22-2234	Submitting Pathologist: Tim Jackson, M.D.	Case #: S09-123445
Patient ID: 23445921	Specimen ID: 232323233	Req #:

Bladder / Urothelial Biopsy

- F) Bladder, Trigone
- G) Bladder, Prostatic Urethra

GROSS DESCRIPTION

- A) Round, pink-tan soft tissue received in formalin measuring 0.1 cm: 1 piece(s) submitted in 1 cassette(s).
- B) Round, pink-tan soft tissue received in formalin measuring 0.1 cm: 1 piece(s) submitted in 1 cassette(s).
- C) Round, pink-tan soft tissue received in formalin measuring 0.1 cm: 1 piece(s) submitted in 1 cassette(s).
- D) Round, pink-tan soft tissue received in formalin measuring 0.1 cm: 1 piece(s) submitted in 1 cassette(s).
- E) Round, pink-tan soft tissue received in formalin measuring 0.1 cm: 1 piece(s) submitted in 1 cassette(s).
- F) Round, pink-tan soft tissue received in formalin measuring 0.1 cm: 1 piece(s) submitted in 1 cassette(s).
- G) Round, pink-tan soft tissue received in formalin measuring 0.1 cm: 1 piece(s) submitted in 1 cassette(s).

COMMENTS

Immunohistochemical stains (CD44, Cytokeratin 20, and p53) performed on (D) support the diagnosis.

If you have any questions on this report please do not hesitate to contact the BioVantra client support center at (866) 627-8221.

Peter A. Tsvivis, M.D.
Pathologist Electronic Signature

03/23/2009
Date

Photomicrograph is a symbolic representation of the key findings of the pathology report. The photomicrograph is not intended to replace a complete review and reading of the final diagnostic report provided.